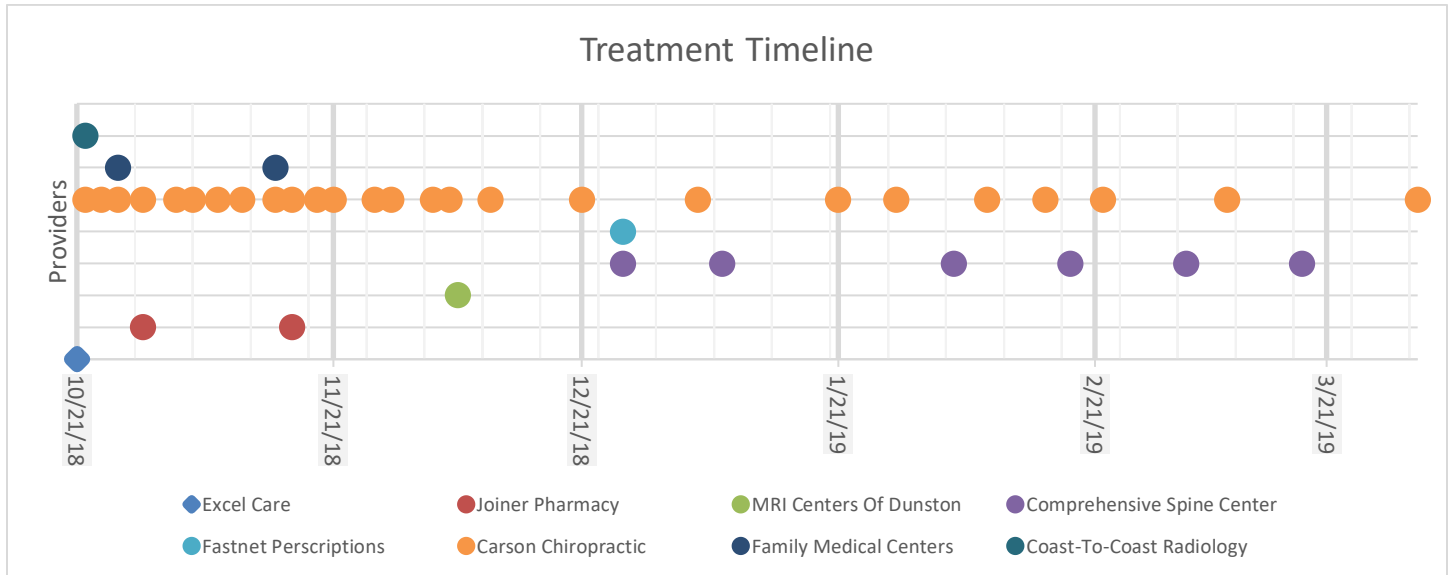


Casentric Injury and Medical Analysis Report

Claim Number: 12345

Reviewer: Sandra Danforth, MSN, RN

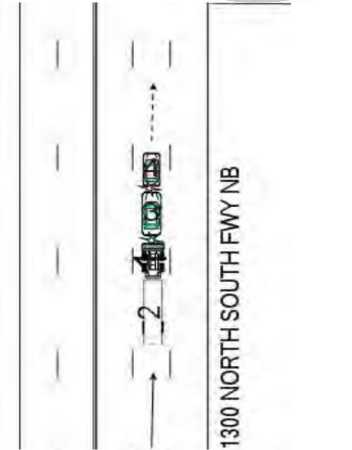
Overview of Treatment



Past Medical History: No medical history, 1 unspecified unrelated surgery in past. Married to co-claimant, 1 child, employed as an architect at time off loss. Smokes cigarettes, denies alcohol intake, illicit drug use. No exercise. Highest level of education, some college. Spanish first language, required translator at provider encounters. [MP 216; 248-249; 114; 122]

10/20/18: 30 yo male, restrained driver, **static** on freeway when struck from behind by a truck tractor towing unit unable to fully break, unknown if loaded, and forced into bumper of car in front of claimant vehicle. Hit head on head rest. Impact occurred in a construction zone with posted speed limit of 60 MPH and workers present. No air bag deployment, no reported injuries, no emergency care. No loss of consciousness. No vehicles towed from scene. [MP 8-11; 176] Images of vehicle damage¹:

¹ Note first photo displaying no airbag deployment.



10/21/18: JPS ROI Service Area, ED evaluation, Dr. Deborah Manning, 01:15 p.m. – 03:14 p.m. Complained of 5/10² moderate to severe pain in neck, upper back, headache, mild right hand numbness following MVC day prior in which he was rear-ended resulting in airbag deployment. Denied loss of consciousness (LOC), headache, nausea, vomiting. No report of striking any body parts within the vehicle. Exam significant for cervical/thoracic spinous tenderness, normal unmeasured range of motion (ROM), no focal neurological deficits. Imaging:

CT Cervical Spine: No acute abnormality. [MP 43-44]

CT Thoracic Spine: No acute abnormality. [MP 45]

CT Head: No acute abnormality. [MP 43-44]

Administered oral narcotic pain medication resulting in improvement in symptoms. Diagnosed MVC, neck/thoracic pain, headache. Discharged to home in stable condition, prescription provided for NSAID and muscle relaxant, instructed to follow-up as an outpatient. [MP 33-40]

10/22/18-04/01/19: Carson Chiropractic, Drs. Jose Guerra and Carina Sanchez, total of 27 encounters. Initially complained of 7/10 pain in neck, mid/low back, right wrist, and headache following MVC on 10/22/18. Weight 214 pounds, BMI 30.7, obese. Initial exam significant for cervical/lumbar/thoracic/right wrist tenderness with unmeasured restricted ROM. Multiple positive orthopedic maneuvers. Normal strength, tone, reflexes. Diagnoses: cervical/thoracic/lumbar/right wrist pain/strain, lumbar radiculopathy, muscle spasm/contracture. Recommended electrical stim, heat/cold treatment traction, XR imaging of spine and elbow. [MP 213-215; 216-219] Imaging:

² Example of pain scale:

- 0: Pain free
- 1: Very minor annoyance-occasional minor twinges
- 2: Minor annoyance-occasional
- 3: Annoying enough to be distracting
- 4: Can be ignored if you are really involved in your work, but still distracting,
- 5: Can't be ignored for more than 30 minutes.
- 6: Can't be ignored for any length of time, but you can still go to work and participate in social activities.
- 7: Make it difficult to concentrate, interferes with sleep, you can still function with effort
- 8: Physical activity severely limited. You can read and converse with effort. Nausea and dizziness may occur.
- 9: Unable to speak, crying out or moaning uncontrollable- pain makes you pass out.
- 10: Unconscious. Pain makes you pass out.

XR Cervical Spine: 1) No evidence of fracture or dislocation. 2) Complete loss of cervical lordosis³. 3) Marked restriction of motion⁴. 3) Arthritic changes. [MP 259]

XR Thoracic Spine: No fracture or dislocation, abnormal and unrelated lung/abdominal findings. No degenerative findings. [MP 260]

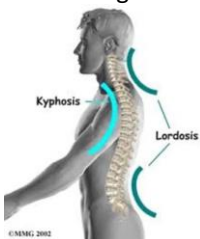XR Lumbar Spine: 1) No fracture or dislocation. 2) Pronounced reduction in lumbar lordosis. 3) No significant degenerative changes. [MP 261]

XR Right Wrist: Normal. [MP 262]

Claimant attended therapy consistently, approximately twice weekly through December 2018. Pain levels decreased from all areas 8/10 to wrist 2/10, neck 2/10, mid/low back 5/10. **Never any complaints of headache or neurological symptoms.** Response to treatment never documented, treatment plan not adjusted. Discussed 12/06/18 lumbar MRI results and referred to orthopedic consultation on 12/10/19. [MP 223-246] Thereafter, claimant attended therapy only on 4 occurrences in 12/18, 3 occurrences in 01/19 & 02/19; 1 occasion in 03/19. Final visit 04/01/19, claimant reported **ALL PAIN RESOLVED**. Exam completely normal with pain free unrestricted cervical/thoracic/lumbar/wrist ROM and all negative orthopedic maneuvers. Noted to have met maximum medical improvement and released from care. Final encounter with this provider. [MP 220-222] **Final encounter with nearly identical charting and recommendations to co-claimant.**

10/26/18 – 11/14/18: FAMILY Medical Centers, Dr. Phillip Ramsey. Two encounters. Initial complaint of severe headaches, radiating pain in neck and mid/low back, bilateral shoulders following MVC⁵. **NO wrist complaints, no headache.** Claimant again reported airbag deployment and being taken to the hospital for evaluation⁶. Exam significant for cervical/lumbar/thoracic/bilateral shoulder tenderness with unmeasured restricted ROM. Multiple positive orthopedic maneuvers. Normal strength, tone; decreased upper and lower extremity reflexes⁷. **Wrist not examined.** Diagnoses: traumatic headache, cervical/thoracic/lumbar/shoulder pain/strain, cervicocranial syndrome, cervical/thoracic/lumbar segmental and somatic dysfunction, muscle spasm, lumbar/cervical radiculitis/neuritis. Recommended continued PT⁸,

³ Lordosis: Natural curvature of the spine. Loss of lordosis refers to lack of the curve in the neck or back; can be caused by things such as degenerative disc disease and muscle spasms. Image:



⁴ Unknown meaning of marked restriction of motion, and how it can be calculated on a plain film in which a patient is lying still.

⁵ First complaint of headaches and shoulder pain, NEVER mentioned this to Carson Chiropractic in the 6 months of treatment

⁶ False. Airbags did not deploy; claimant went with wife to the hospital the following day.

⁷ Note that reflexes were documented as completely normal four days earlier at Carson Chiropractic.

⁸ Note claimant was undergoing chiropractic care, not PT, and had attended only two sessions since the loss six days prior.

cervical/lumbar MRI⁹, trigger point injections¹⁰ due to continued pain¹¹, and NSAIDs/muscle relaxant/topical pain cream. Instructed to return in 2 weeks. [MP 248-253] On 11/14/18, complained of 6/10 pain in all areas. No noticeable change in exam findings. Recommended continued therapies, facet injections, MRI imaging, oral steroids, oral narcotics, lumbar brace. Instructed to return in 2 weeks. [MP255-258] Last encounter with this provider. **Both encounters with nearly identical charting and recommendations to co-claimant.**

12/06/18: MRI Centers of Dunston, ordering provider, Carina Sanchez; indication of low back pain.

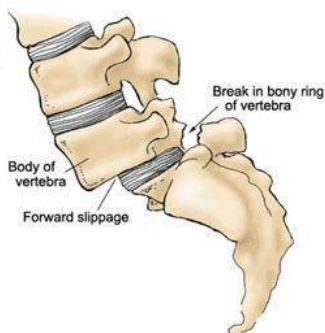
MRI Lumbar Spine: 1) L5-S1 grade 1, 3mm anterolisthesis¹² with uncovering of intervertebral disc. Acute/subacute posterior left central 3.5mm disc protrusion¹³ with a superimposed 8mm left posterior left subarticular annular

⁹ MRI: Literature indicates that an MRI should not be obtained until 4-6 wks after symptoms began, and then only after conservative treatment has been ineffective. Interestingly, the literature states that obtaining an MRI without supporting clinical findings and without an initial trial of conservative treatment “can be detrimental, encouraging patients to take a passive role in their care” and patients may focus on an abnormal, and “perhaps incidental” MRI finding rather than on the need to rehab the knee, and may ultimately undergo procedures that are not necessarily indicated. [SOURCE](#)

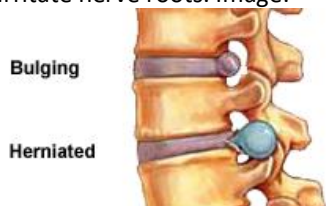¹⁰ Steroid injections: Performed to help reduce inflammation and pain associated with nerve root compression; a procedure which is temporary in nature and is indicated after a trial of conservative therapy of physical therapy and/or chiropractic treatments. At this point a conservative therapy had not been attempted.

¹¹ Again, note that MVC was only 6 days earlier

¹² Anterolisthesis: Spine condition in which the upper vertebral body, the drum-shaped area in front of each vertebrae, slips forward onto the vertebra below. The amount of slippage is graded on a scale from 1 to 4, often due to sudden blunt force or fractures. Image:



¹³ Disc herniation: Also called ruptured disks or slipped disks, although the whole disk does not rupture or slip, it protrudes out of its' normal space. Usually comes on abruptly and usually affects one individual nerve root; sometimes caused by an acute injury. Compared with a bulging disk, a herniated disk is more likely to cause pain because it generally protrudes farther and is more likely to irritate nerve roots. Image:

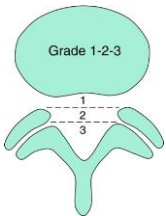


Note that size of protrusion does not matter. The larger the disc herniation does not necessarily correlate with more severe symptoms, as the size of the herniation has nothing to do with the quantity of pain or disability of the affected person experiences. A tiny contained herniation can result in just as much patient-suffering and disability as a very large bulge. Bulges can be graded on how

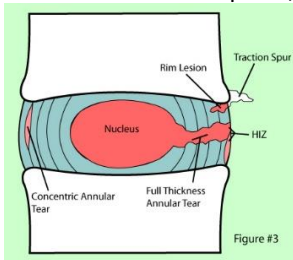
fissure¹⁴. Disc protrusion contacts left S1 nerve root in the lateral recess with associated mild left neural foraminal stenosis¹⁵. [MP 89-90]

12/26/18 -02/04/19: Comprehensive Spine Centers, Dr. Scott Flannery, referred by Guerra at Carson Chiropractic, total of 7 encounters. Initially complained of headaches low back pain, vertigo, vision changes, attention/memory deficits, anxiety¹⁶. Described details of the loss, "On highway when rear ended by a semi which caused her to lose control and was hit by second vehicle in the middle of the car¹⁷." **Denied neck/shoulder/wrist pain¹⁸**. Complains of difficulty maintaining detail in occupation as architect, standing/sitting for long periods, completing housework, going on walks with family. **Stated can no longer workout at gym, after first stating he does not exercise.** Stated missed unspecified amount of work post loss. [MP 114; 119] Exam significant for lumbar tenderness with restricted, measured ROM, normal strength and sensation, decreased bilateral lower extremity reflexes, all negative orthopedic maneuvers. Neck not examined. Reviewed

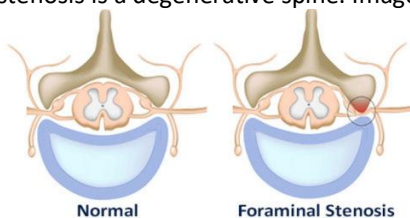
much encroachment is present on the nerves. Grade 1 lesions have little impact and grade 3 may have the most impact on nerve compression. The measurement of bulge in millimeters only states how much bulge is present. It is more important to determine where the material extends to correlate resulting symptoms from nerve compression. Image:



¹⁴ Annular fissure/tear: Discogenic condition, commonly degenerative in nature, usually occurs when the fibers that make up the tough, outer covering of the intervertebral disc either break or separate; normally caused /due to age and wear on the vertebrae discs, eventually causing major pain in the lumbar spine. The annulus can tear or rupture anywhere around the disc. If it tears and no disc material is ruptured, it is called an annular tear. Image:



¹⁵ Foraminal stenosis: Narrowing or tightening of the openings between the bones (foramen) in the spine. The risk of neural foraminal stenosis, which can be caused by general wear and tear, increases with age. The most common cause of neural foraminal stenosis is a degenerative spine. Image:



¹⁶ New symptoms reported 2.5 months post loss. Never reported to other providers during 6 months of treatment.

¹⁷ Note these details are false; refer to police report in which it was noted her vehicle was stopped when struck from behind, pushing her into the car in front.

¹⁸ Note that in the weeks surrounding this evaluation, claimant continued to report to Gomez at Carson Chiropractic of neck and shoulder pain but did not mention it on this date. New onset of significant neurological symptoms that were also never mentioned to other providers in the 6 months of care rendered.

12/06/18 MRI. Diagnoses: lumbar pain/strain/radiculitis/ruptured disc injury, post traumatic headache/anxiety, dizziness, insomnia, attention concentration deficit. Recommended continued therapy/home exercises, course of oral steroids, lumbar facet injections, testing for brain injury. Instructed to return in 2 weeks. No review or correspondence with Carson Chiropractic. [MP 118-123] Follow-up visits 01/07/19 & 02/04/19 claimant returned, stating no improvement in headache, low back pain, or neurological symptoms¹⁹. No change in exam, facet injections recommended. [MP 133-137; 162-166]

01/25/19: Comprehensive Spine Centers, Dr. Scott Flannery.

Neurokinetic I-PAS²⁰: Abnormal study, abnormal eye movements in setting of post concussive syndrome indicates suboptimal brain function. [MP 146]

02/18/19-04/29/19: Comprehensive Spine Centers, Dr. Scott Flannery. Lumbar medial branch block at L3,4,5; completed on 02/18/19, tolerated well, after which reported 80% improvement in back pain, no change in headaches. On 03/04/19 claimant reported headaches and back pain improved, although experienced occasional spurts of pain, not as severe as initial presentation. No change in exam. Released from care, instructed to continue home exercises, return as needed. No further encounters with this provider. [MP 175-176; 187-191; 200-203]

Primary Questions

- Are the spinal strains/bulging discs related?

Unlikely

There are many causes for this injury. Unknown speed at impact causing minimal damage and whiplash type injury can cause a ligamentous strain of the neck and back. The claimant is diagnosed with anterolisthesis which is a pre-existing condition. While his MRI indicates he has an “acute tear”, the radiologist does not clarify how they are able to judge the age and what an “acute” tear is. The claimant was also inconsistent in his complaints to different providers, sometimes complaining of neck pain or shoulder pain or wrist pain, none at others. (Lumbar complaints were consistent.) The claimant presented varying versions to providers of the degree of damage to his vehicle when representing the force of impact. The claimant indicates in the ER he was restrained which means his low back would have been well protected against hyperflexion and extension needed to cause the pressure required to herniate a disc at L5-S1.

- Is the concussion/head injury related?

Unconfirmed

A diagnosis of concussion is not made. The list of diagnoses relative to the head injury are based on claimant’s complaints, not on the basis of a concussion examination. Post concussive symptoms can include headache, balance issues, memory loss, forgetfulness, etc. In order to determine the relatedness of a concussion, it would first be necessary to have a clinically definitive examination that confirms the diagnosis. Note that it is unclear why the headrest on the claimant’s seat is dismantled in the photos. Also note that claimant inconsistently complained to varying providers how severe his symptoms were, whereby he NEVER stated to chiropractic treaters over a 6 month time frame that he ever suffered from any headaches or concussive symptoms, but to orthopedist that they were unrelenting and without change in character.

¹⁹ Note that while claimant reported terrible headaches, neurological symptoms, and low back pain, in the very same week she stated to Carson Chiropractic that headaches had improved to a 1/10 and low back pain was 5/10.

²⁰ Neurokinetic I-PAS: Clinical assessment of neurological eye tracking and eye reflexes to evaluate patients suffering from dizziness and vertigo from concussions. Unknown extent of research to support validity of this testing. [Website](#)

- Pre-existing Conditions

Yes

Cervical arthritic changes and lumbar foraminal stenosis identified on imaging one day post loss indicate a condition that predates a loss, However, impact likely caused exacerbation of this chronic problem.

- Comorbidities?

Yes

Obesity. Claimant was obese at time of loss and had a documented weight gain of 34 pounds in the following month. Obesity negatively impacts the musculoskeletal system, whereas excessive weight increases mechanical stress to the joints and tissues of the body and induces physical limitations and bodily pain. Self-reported bodily pain symptoms increase with progressively higher body mass index (BMI) values. The confluence of pain and weight-related physical discomfort exacerbates the decline in physical function, a serious issue because chronic pain mediates obesity-induced impairment and the eventual decline of fitness and health-related quality of life²¹.

Current smoker at time of loss. Claimant inconsistently reported tobacco abuse. Regardless, if he was indeed a smoker, the effects of tobacco abuse could have negatively impacted his recovery. Recent studies have shown that chronic neck pain is worsened by smoking and has long been associated with an increased risk of low back pain. A new study presented at the Association of Academic Physiatrists (AAP) annual meeting has found that smoking is also a culprit in the development of degenerative cervical disc disease, a degenerative condition that causes chronic neck pain²².

- Intervening cause?

None identified

- Was all the treatment necessary?

Facet block injection - Questionable

Steroid injections are performed to help reduce inflammation and pain associated with nerve root compression; a procedure which is temporary in nature and is indicated after a trial of conservative therapy of physical therapy and/or chiropractic treatments. Injections were not performed until 4 months post loss and a trial of chiropractic treatment. Based on MRI studies, claimant did have evidence of mild foraminal narrowing which could cause nerve root compression and subsequent lumbar pain. **However, please note that the injections were performed at L3, L4, and L5, yet MRI showed disc injury only at L5-S1. There was no rationale for treating the higher levels (L3, L4). Additionally, the co-claimant received the exact same injections on the same date, same location, in an area where no disc disease was evident.**

Chiropractic care – yes, initially

Chiropractic treatment is a proven treatment modality in the setting of bulging discs and whiplash injury by employing adjustment methods that specifically address joint restriction and dysfunction, thereby helping to relieve symptoms. A treatment duration of approximately 6-8 weeks at a frequency of 2x/week is appropriate. However, response to treatment was never documented and subsequent treatment plan never altered, suggesting the final 3 months of therapy were unnecessary.

²¹ [SOURCE](#)

²² [SOURCE](#)

- Questionable Procedure?
Yes
Neurokinetic I-PAS testing validity and clinical application is unknown.
- Were there any issues encountered during the recovery process?
None identified
- Has the claimant fully recovered from the injuries?
Unknown
Per 04/29/19 Carson Chiropractic final encounter, all problems had resolved and completely normal exam was documented. Per 03/18/19 Comprehensive Spine Center final exam, headache and low back pain were nearly resolved. Per 08/19 Demand, claimant reports continued difficulty with ADLs, post concussive symptoms, anxiety related to collisions, and bouts of depression. These complaints cannot be substantiated as there are no medical records produced after 04/29/19 to determine her current state of health.
- Is there any claim that the claimant has a permanent impairment?
No

Other Observations (optional by request of adjuster)

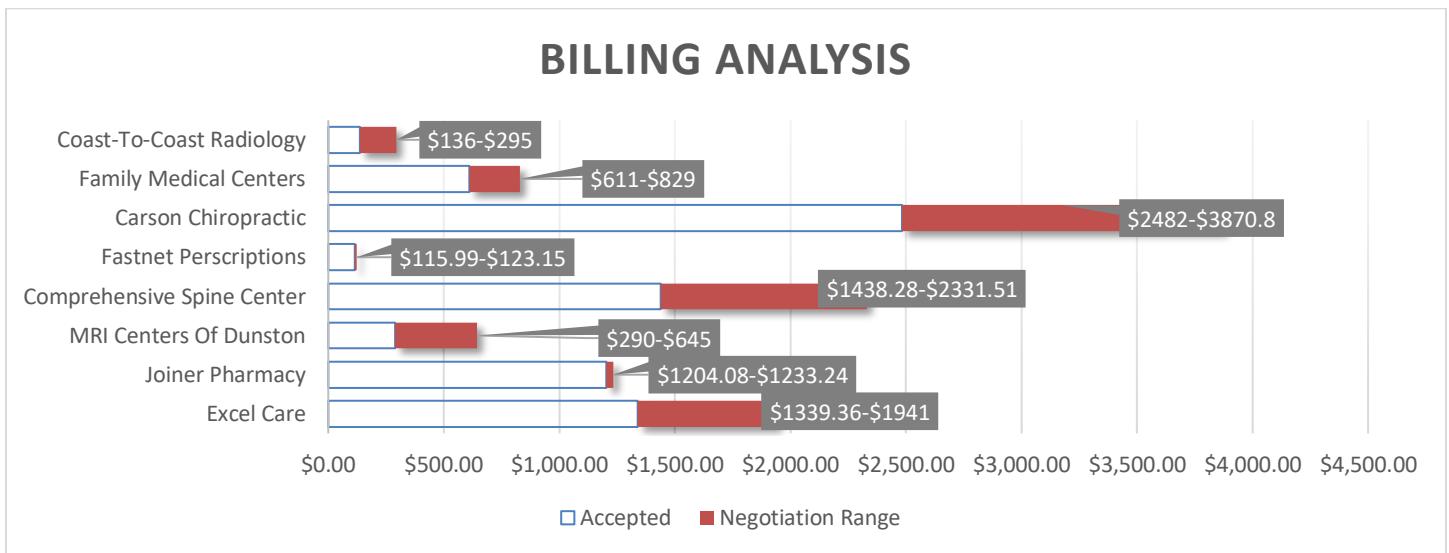
Additional records to obtain for further case development:

- Prior PCP medical records to determine pre/post loss state of spinal health.

Other significant observations about:

- Inconsistencies in mode of impact to different providers, at one point stating hit from behind then t-boned and report of airbag deployment, both refuted in Police Report. This is concerning for litigious behavior as it suggests more severe mode of impact, thereby altering providers' plan of care.
- Inconsistent report of physical complaints provider to provider.
- Concerningly similar complaints, services, and injuries with co-claimant.

Billing Analysis



Provider	Billed	Reduced To	Reasons for Reduction
Excel Care	\$8,676	\$1,339.36-\$1,941	<p>The charges for services are in excess of reasonable compensation in this area. Charges are reduced to reflect reasonable compensation as follows:</p> <ul style="list-style-type: none"> Hydrocodone- Acetaminophen reduced from \$3 to \$0.36-\$3.23 CT C Spine reduced from \$2258 to \$193-\$315 CT Head reduced from \$2991 to \$294-\$501 CT T Spine reduced from \$2617 to \$193-\$315 ER Visit LVL 3 reduced from \$768 to \$620-\$923
Joiner	\$2,026.33	\$1,204.08-\$1,233.24	<p>The charges for medication are in excess of reasonable compensation in this area. Charges are reduced to reflect reasonable compensation as follows:</p> <ul style="list-style-type: none"> Meloxicam 30 Qty reduced from \$149.99 to \$3-\$5.2 Tizanidine 15 QTY reduced from \$149.99 to \$5.39-\$10.21 Shipping Fee reduced from \$15 to \$15-\$15 Apap/ Codeine 45 Qty reduced from \$194.06 to \$9.62-\$13.43 Methylprednisone 21 Qty reduced from \$302.6 to \$112.99-\$131.13
MRI Centers of Dunston	\$2,634.00	\$290-\$645	<p>The charges for services are in excess of reasonable compensation in this area. Charges are reduced to reflect reasonable compensation as follows:</p> <ul style="list-style-type: none"> MRI L Spine reduced from \$2634 to \$290-\$645

Comprehensive Spine	\$11,860.00	\$1,438.28-\$2,331.51	<p>The second level injection is questionable as there is no clinical explanation for including the injection at this level. Up to the total amount of this injection can be challenged (up to \$304.13 when reduced to reasonable compensation).</p> <p>The charges for services are in excess of reasonable compensation in this area. Charges are reduced to reflect reasonable compensation as follows:</p> <ul style="list-style-type: none"> • New Patient Visit LVL 4 reduced from \$900 to \$187-\$318 • EST Patient Visit LVL 3 reduced from \$450 to \$85-\$144 • Lumbar Facet Injection LVL 1 reduced from \$6000 to \$649-\$811 • Lumbar Facet Injection LVL 2 reduced from \$2250 to \$243.38-\$304.13 • Kenelog reduced from \$300 to \$17.28-\$18.38
FASTNET Prescriptions	\$204.68	\$115.99-\$123.15	<p>The charges for medication are in excess of reasonable compensation in this area. Charges are reduced to reflect reasonable compensation as follows:</p> <ul style="list-style-type: none"> • Cyclobenzaprine 15 Qty reduced from \$73.95 to \$3-\$8.42 • Methylprednisone 21 Qty reduced from \$114.73 to \$112.99-\$131.13 <p>Shipping charge of \$16 removed as unjustified.</p>
Carson Chiropractic	\$7,397.70	\$2,482.00 - \$3,870.80	<p>As noted above, the reasonable period of treatment is 6-8 weeks. This results in a reduction of \$2,374.10 - \$2,931.90.</p> <p>The charges for services are in excess of reasonable compensation in this area. Charges are reduced to reflect reasonable compensation as follows:</p> <ul style="list-style-type: none"> • New Patient Visit LVL 4 reduced from \$262.1 to \$187-\$318 • Elect Stim reduced from \$30 to \$18-\$29 • Mechanical Traction reduced from \$28.10 to \$24-\$28.10 • C Spine XR reduced from \$250 to \$35-\$85 • T Spine XR reduced from \$150 to \$35-\$85 • L Spine XR reduced from \$158 to \$35-\$85 • Wrist XR reduced from \$63 to \$31-\$74 • CMT Spinal reduced from \$54 to \$33-\$56 • Massage Therapy reduced from \$45 to \$46-\$57 • Therapeutic Exercises reduced from \$106.8 to \$43-\$61 • CMT Spinal reduced from \$75 to \$33-\$56. <p>A charge of \$100 for a report is removed from the bill.</p>

FAMILY Medical	\$1,950	\$611-\$829	<p>The charges for services are in excess of reasonable compensation in this area. Charges are reduced to reflect reasonable compensation as follows:</p> <ul style="list-style-type: none"> • New Patient Visit LVL 4 reduced from \$950 to \$187-\$318 • Medical Reports reduced from \$300 to \$300-\$300 • EST Patient Visit LVL 4 reduced from \$700 to \$124-\$211
Allied Radiology	\$295	\$0 - \$295	The radiology fees are already included in the cost of diagnostic films. Up to the total amount can be challenged.
Total	\$35,043.71	\$7,616.71-\$11,268.7	